

Malformation in three anuran species from a preserved remnant of Atlantic Forest in southeastern Brazil

Malformação em três espécies de anuros de um remanescente preservado de Mata Atlântica no Sudeste do Brasil

Alexander Tamanini Mônico¹, Thiago Silva-Soares¹, Esteban Diego Koch²

- 1 Instituto Nacional da Mata Atlântica, Museu de Zoologia Professor Mello Leitão, Programa de Capacitação Institucional, Avenida José Ruschi 4, Centro, Santa Teresa 29.650-000, Espírito Santo, Brazil
- 2 Universidade Regional de Blumenau, Curso de Graduação em Ciências Biológicas, Rua Antônio de Veiga 140, Itoupava Seca, Blumenau 89030-903, Santa Catarina, Brazil

Corresponding author: Alexander Tamanini Mônico (alexandermonico@hotmail.com)

Academic editor: A. M. Leal-Zanchet | Received 29 January 2019 | Accepted 31 March 2019 | Published 22 July 2019

Citation: Mônico AT, Silva-Soares T, Koch ED (2019) Malformation in three anuran species from a preserved remnant of Atlantic Forest in southeastern Brazil. *Neotropical Biology and Conservation* 14(2): 213–220. <https://doi.org/10.3897/neotropical.14.e37919>

Abstract

Records of malformation in amphibians have significantly increased on a global scale. The main causes of malformations are linked to environmental contaminants, and records in preserved environments are uncommon. We reported malformations in three anuran species belonging to three families: *Crossodactylus timbuihy* (Hylodidae), *Proceratophrys schirchi* (Odontophrynidae) and *Thoropa miliaris* (Cycloramphidae). All records were found within the Reserva Biológica Augusto Ruschi, a well-preserved protected remnant of Atlantic rainforest located in the mountains of the state of Espírito Santo, southeastern Brazil. The malformations detected were hemimelia (long bone shortened) with ectrodactyly (digit absent) and brachydactyly (digit shortened) in *C. timbuihy*, microphtalmia (small eye) in *P. schirchi* and ectrodactyly in *T. miliaris*. Further studies are recommended to enable a better understanding about the incidence and causes of malformations within preserved areas.

Resumo

Registros sobre malformações em anfíbios têm aumentado significativamente em escala global. Os principais agentes causadores de malformações estão ligados à contaminação ambiental, sendo pouco comuns registros em áreas naturais preservadas. Reportamos malformações em três espécies de anfíbios anuros pertencentes a três diferentes famílias: *Crossodactylus timbuhy* (Hylodidae), *Proceratophrys schirchi* (Odontophrynidae) e *Thoropa miliaris* (Cycloramphidae). Todos os registros foram realizados no interior da Reserva Biológica Augusto Ruschi, uma área de Mata Atlântica bem preservada nas montanhas do Estado do Espírito Santo, sudeste do Brasil. As malformações detectadas foram hemimelia (redução de ossos longos) com ectrodactilia (ausência de dígitos) e braquidactilia (redução de dígitos) em *C. timbuhy*, microftalmia (redução do olho) em *P. schirchi* e ectrodactilia em *T. miliaris*. Recomendamos estudos adicionais para a compreensão da incidência e causas de malformações em ambientes preservados.

Keywords

amphibian, brachydactyly, conservation, ectrodactyly, hemimelia, microphthalmia, protected area

Palavras-chave

anfíbios, braquidactilia, conservação, , ectrodactilia, hemimelia, microftalmia, unidade de conservação

Malformations in anurans are not a recent development in herpetology, since the first register was in 1554 (Gesner 1554); they have been reported in all continents for more than 400 species (Henle et al. 2017). The frequency of malformations reports has increased with time, and recently come to a distinguished breakout (García-Muñoz et al. 2010; Johnson et al. 2010). Malformations were detected in different anuran families, genera, as well as in inhabitants of different microhabitats (Piha et al. 2006; Medina et al. 2013). These deformities may denote environmental complications, which also may impact on other organisms; thus, these reports are important to help understanding malformation dynamics (Meteyer 2000; Roy 2002; Johnson et al. 2003). There are various possible causes of amphibian deformations, including genetic and environmental factors, such as parasitic infestation (Johnson et al. 1999; Kiesecker 2002), microbial diseases and other disorders (Sessions and Ruth 1990), elevation of UV-B radiation (Ankley et al. 2000), and the major factor: chemical agents, most of them found in agribusiness pollution (Ouellet et al. 1997; Hayes et al. 2002; Lannoo 2008; Koleska and Jablonski 2016). All these sources may cause homeostatic imbalances that can result in incorrect developments of anurans (Ballengé and Sessions 2009). Herein, we reported three sympatric individuals from different families with morphological deformities.

The specimens were found in 2018 between January and February during nocturnal surveys at Reserva Biológica Augusto Ruschi (Rebio AR; 19.9061S, 40.5622W, WGS 84; 786 m a.s.l.), municipality of Santa Teresa, state of Espírito Santo, southeastern Brazil. The remnant is a protected area that comprehends well-preserved forests surrounded by agricultural lands, mainly crops of coffee, banana and *Eucalyptus* spp. In these agricultural lands there is an extensive use of agrochemicals

(Gatti et al. 2014; Ferreira et al. 2016). Deformities classification followed Meteyer (2000). The specimens were deposited in the Zoological Collection of Instituto Nacional da Mata Atlântica (former Museu de Biologia Mello Leitão – MBML), Santa Teresa, Espírito Santo, Brazil.

On 13 January 2018, we found the first specimen, a juvenile individual of *Proceratophrys schirchi* (Miranda-Ribeiro, 1937) (voucher number: MBML 11149; SVL = 19.6 mm) with a small right eye, which we recognized as microphthalmia, and a normal left eye (Fig. 1A–C). Only 53 cases of microphthalmia in anurans were reported worldwide (Henle et al. 2017). The only record in Brazilian anurans was in hybrids of *Rhinella icterica* (Spix, 1824) with *Rhinella crucifer* (Wied-Neuwied, 1821), where hybridization seemed to have caused the deformities (Haddad et al. 1990). There is evidence that increased rates of microphthalmia in anurans may be caused by exposition to heavy metals (Fort et al. 2006). Another possible cause of microphthalmia has been suggested to be caused by Ranavirus FV³ (Burton et al. 2008), but there was no literature on experimental test to evidence it. Dias and Carvalho-e-Silva (2012) registered a case of polymelia (when more than two fore or rear limbs are presents) in adults of *Proceratophrys appendiculata* (Günther, 1873); they also recorded cases of eye abnormalities (microphthalmia and anophthalmia), but only in tadpoles of this species.

The second malformed individual was a metamorphosing froglet of *Crossodactylus timbuihy* Pimenta et al. 2014. This anuran (MBML 11196; SVL = 11.2 mm) was collected on 17 January 2018 on a rocky outcrop close to a stream, and a careful examination exposed a case of hemimelia with ectrodactyly and brachydactyly in the left hindlimb, i.e., shortening of tibiafibula and tibia and fibula (hemimelia), only two digits (ectrodactyly), and all of them were short (brachydactyly) (Fig. 2A–D).



Figure 1. Juvenile of *Proceratophrys schirchi* with microphthalmia in the right eye. (A) Frontal sight of the individual; (B) Affected right eye; (C) Normal left eye.

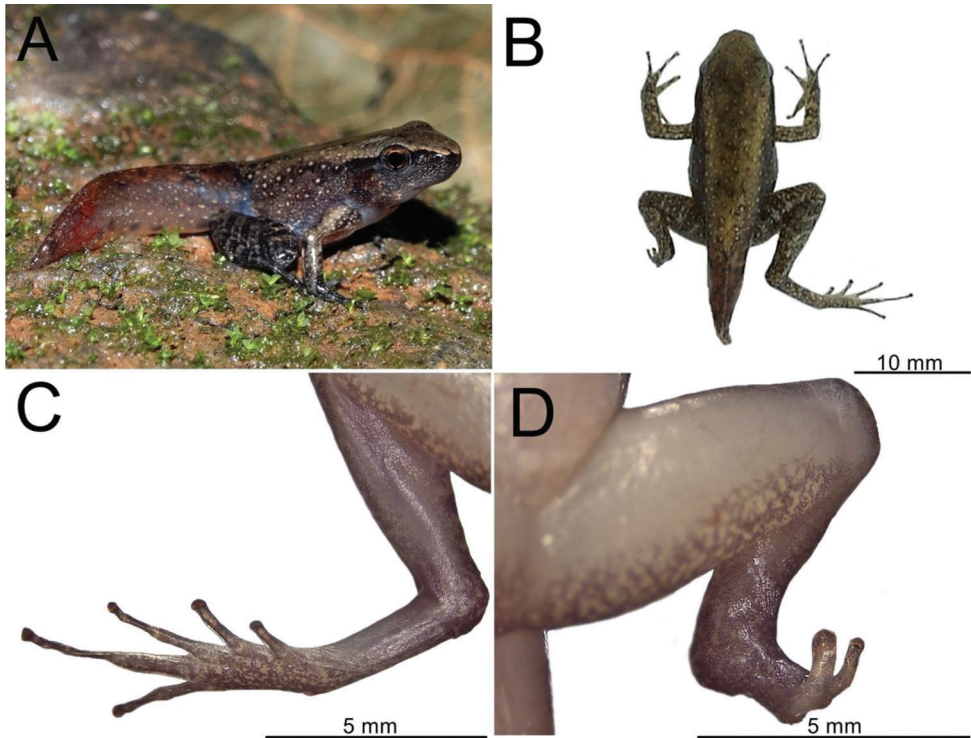


Figure 2. Metamorphic individual of *Crossodactylus timbuhy*. (A) Natural posture of specimen alive; (B) Specimen fixed; (C) Normal hind limb; (D) Malformed hind limb.

Finally, we found an adult male of *Thoropa miliaris* (Spix, 1824) (MBML 11269; SVL= 59.1 mm) in a roadway on 4 February 2018. The individual was alive, but lethargic with scars probably caused by having been run over. The anuran had malformation in the right forelimb, confirmed by absence of scars or injuries on this member (Fig. 3A). A radiography confirmed that tarsus and metatarsus bones were fused (Fig. 3B), and digits were entirely absent (ectrodactyly).

A previous report presented a case of morphological malformation of an adult of *Itapothyla langsdorffii* (Duméril & Bibron, 1841) (Hylidae) in Rebio AR, the same protected area of this study (Mônico et al. 2016). This work reported an individual with a malformed head. Although some cases were documented to occur in neotropical regions (Rojas-Morales and Escobar-Lasso 2013; Brouard and Smith 2014; Mônico et al. 2016), reports of malformed anurans in protected areas are considered uncommon. An estimate determined the baseline for malformations in natural populations as being 5% (Lunde and Johnson 2012). Therefore, it is expected that amphibians in well-preserved areas can have natural osteological deformities as a consequence of intrinsic genetic and developmental imperfections (Lunde and Johnson 2012).

The Reserva Biológica Augusto Ruschi embraces several small rivers and streams with sigmoidal forms that cross all the reserve and adjacent lands (ICMBIO 2002).

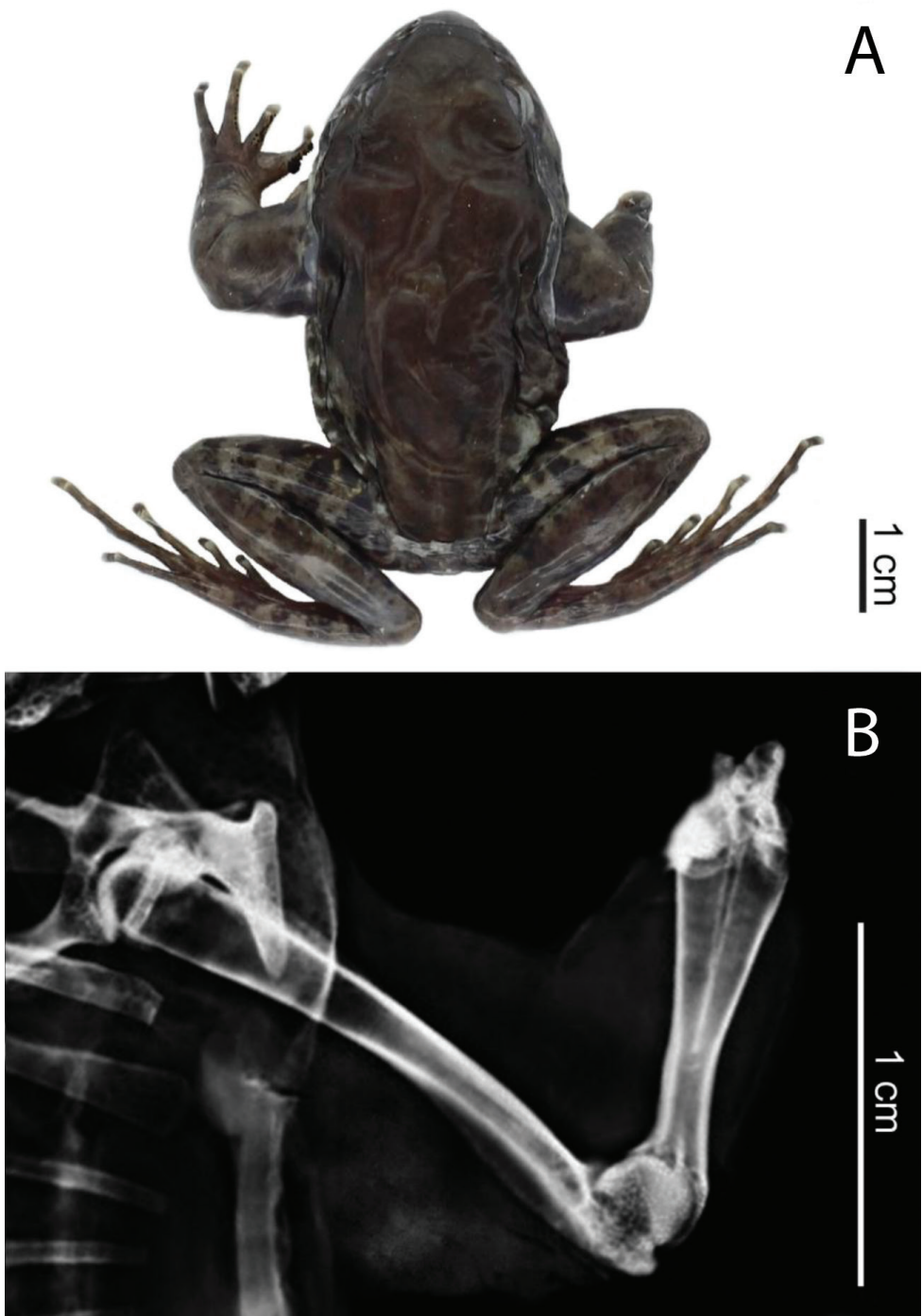


Figure 3. Adult male of *Thoropa miliaris* with malformed right forelimb. (A) Dorsal view with a general perspective of specimen limbs after fixation; (B) Radiography of right forelimb in dorsal view.

We believe that all individuals collected with malformations could be probably contaminated during its embryony developing stage in the rivers or streams within or near the reserve, a hypothesis that needs to be tested. Although we have not identified the causes of the malformations described here, they represent information regarding the first cases of malformations in *P. schirchi*, *C. timbuhy* and *T. miliaris* up to now, besides being novel records in the families Cycloramphidae and Hylodidae.

Acknowledgments

We thank Gabrielly B Tolentino, Kemilly BS Paula and Tatiane M Carmo for their help in fieldwork. We thank the reviewers for their comments. Instituto Nacional da Mata Atlântica and Bromeligenous Project provided technical support. AT Mônico thanks Conselho Nacional de Desenvolvimento Científico e Tecnológico (CNPq grant: 304374/2016-4) for financial support and resources. Instituto Chico Mendes da Conservação da Biodiversidade (ICMBio) provided permits (50.402-5). TSS gratefully acknowledges a grant from FAPES/VALE/FAPERJ No. 01/2015, process number 527/2016. This work is part of the project 'Herpeto Capixaba: for the knowledge and conservation of amphibians and reptiles of Espírito Santo'.

References

- Ankley GT, Tietge JE, Holcombe GW, Defoe DL, Diamond SA, Jensen KM, Sigmund JD (2000) Effects of laboratory ultraviolet radiation and natural sunlight on survival and development of *Rana pipiens*. *Canadian Journal of Zoology* 78(6): 1092–1100. <https://doi.org/10.1139/z00-040>
- Ballengée B, Sessions SK (2009) Explanation for missing limbs in deformed amphibians. *Journal of Experimental Zoology Part B: Molecular and Developmental Evolution* 312(B): 770–779. <https://doi.org/10.1002/jez.b.21296>
- Brouard JP, Smith P (2014) *Elachistocleis bicolor* (Amphibia: Anura: Microhylidae) and *Eupemphix nattereri* (Amphibia: Anura: Leuiperidae): Morphological abnormalities from Reserva Natural Laguna Blanca, Paraguay. *Herpetologia Brasileira* 3(3): 85–87. <http://sbherpetologia.org.br/wp-content/uploads/2017/05/hb-2014-03-p.pdf>
- Burton EC, Miller DL, Styer EL, Gray MJ (2008) Amphibian Ocular Malformation Associated with Frog Virus 3. *Veterinary Journal (London, England)* 177(3): 442–444. <https://doi.org/10.1016/j.tvjl.2007.05.006>
- Dias PHS, Carvalho-e-Silva AMPT (2012) Records of abnormalities in *Proceratophrys appendiculata* (Günther, 1873) (Anura: Cycloramphidae; Alsodinae). *Herpetology Notes* 5: 197–199. http://www.herpetologynotes.seh-herpetology.org/Volume5_PDFs/Dias_Herpetology_Notes_Volume5_pages197-199.pdf
- Ferreira BE, Beard KH, Crump LM (2016) Breeding Guild Determines Frog Distributions in Response to Edge Effects and Habitat Conversion in the Brazil's Atlantic Forest. *PLoS One* 11(6): 1–13. <https://doi.org/10.1371/journal.pone.0156781>

- Fort DJ, Rogers RL, Bacon JP (2006) Deformities in cane toad (*Bufo marinus*) populations in Bermuda. Part II. Progress towards characterization of chemical stressors. *Applied Herpetology* 3: 143–172. <https://doi.org/10.1163/157075406778116186>
- García-Muñoz E, Rato FJC, Carretero MA (2010) Four types of malformations in a population of *Bufo boulengeri* (Amphibia, Anura, Bufonidae) from the Jbilet Mountains (Marrakech, Morocco). *Herpetology Notes* 3: 267–270. http://www.herpetologynotes.seh-herpetology.org/Volume3_PDFs/Garcia-Munoz_Herpetology_Notes_Volume3_pages267-270.pdf
- Gatti A, Segatto B, Carnelli CC, Moreira DO (2014) Mamíferos de médio e grande porte da Reserva Biológica Augusto Ruschi, Espírito Santo. *Natureza Online* 12(2): 61–68. http://www.naturezaonline.com.br/natureza/conteudo/pdf/02_GattiAetal_061-068.pdf
- Gesner C (1554) *Historiae Animalium liber II: de quadrupedibus ovipari*. Froshover, Zurich, 146 pp.
- Haddad CFB, Cardoso AJ, Castanho LM (1990) Híbridação natural entre *Bufo ictericus* e *Bufo crucifer* (Amphibia: Anura). *Revista Brasileira de Biologia* 50(3): 739–744.
- Hayes TB, Collins A, Lee M, Mendonza M, Noriega N, Stuart AA, Vonk A (2002) Hermaphroditic, demasculinized frogs after exposure to the herbicide atrazine at low ecologically relevant doses. *Proceedings of the National Academy of Sciences of the United States of America* 99(8): 5476–5480. <https://doi.org/10.1073/pnas.082121499>
- Henle K, Dubois A, Vershinin V (2017) A review of anomalies in natural populations of amphibians and their potential causes. *Mertensiella* 25: 57–164. <https://ipae.uran.ru/sites/default/files/publications/users/Henle%20Dubois%20Vershinin%202017%20A%20review%20of%20anomalies.pdf>
- ICMBIO [Instituto Chico Mendes de Conservação da Biodiversidade] (2002) Plano de Manejo da Reserva Biológica Augusto Ruschi. *Diário Oficial da União*, Portaria n. 165, de 24 de dezembro de 2002, Brasil, 280 pp.
- Johnson PTJ, Lunde KB, Ritchie EG, Launer AE (1999) The effect of trematode infection on amphibian limb development and survivorship. *Science* 284(5415): 802–804. <https://doi.org/10.1126/science.284.5415.802>
- Johnson PTJ, Lunde KB, Zelmer DA, Werner JK (2003) Limb deformities as an emerging parasitic disease in amphibians: Evidence from museum specimens and resurvey data. *Conservation Biology Journal* 17(6): 1724–1737. <https://doi.org/10.1111/j.1523-1739.2003.00217.x>
- Johnson PTJ, Reeves MK, Krest S, Pinkney AE (2010) A decade of deformities: advances in our understanding of amphibian malformations and their implications. In: Sparling DW, Linder G, Bishop CA, Krest S (Eds) *Ecotoxicology of amphibians and reptiles*. Second edition. Society for Environmental Toxicology and Chemistry (SETAC) Press, Pensacola, 511–536. <https://doi.org/10.1201/EBK1420064162-c16>
- Kiesecker JM (2002) Synergism between trematode infection and pesticide exposure: A link to amphibian limb deformities in nature? *Proceedings of the National Academy of Sciences of the United States of America* 99(15): 9900–9904. <https://doi.org/10.1073/pnas.152098899>

- Koleska D, Jablonski D (2016) Two cases of unclear hindlimb malformation in *Bombina variegata*. *Ecologica Montenegrina* 9: 56–58. <https://www.biotaxa.org/em/article/view/27901>
- Lannoo M (2008) Malformed frogs: the collapse of aquatic ecosystems. University of California Press, Berkeley, 288 pp. <https://doi.org/10.1525/california/9780520255883.001.0001>
- Lunde KB, Johnson PTJ (2012) A Practical Guide for the Study of Malformed Amphibians and Their Causes. *Journal of Herpetology* 46(4): 429–441. <https://doi.org/10.1670/10-319>
- Medina RG, Ponssa ML, Guerra C, Araóz E (2013) Amphibian abnormalities: Historical records of a museum collection in Tucuman Province, Argentina. *Journal of Herpetology* 23: 193–202. <https://www.ingentaconnect.com/openurl?genre=article&issn=0268-0130&volume=23&issue=4&spage=&epage=&aulast=Medina>
- Meteyer CU (2000) Field guide to malformations of frogs and toads with radiographic interpretations. Biological Science Report, USGS/BRD/BSR, 2000-0005. <https://pubs.er.usgs.gov/publication/53882>
- Mônico AT, Ferreira RB, Lauvers WD, Mattos RO, Clemnte-Carvalho RBG (2016) *Itapotihyla langsdorffii* (Perereca Castanhola; Ocellated Treefrog): Head Abnormality. *Herpetological Review* 47(2): 278–279. <https://ssarherps.org/herpetological-review-pdfs>
- Ouellet M, Bonin J, Rodrigue J, Desgranges JL, Lair S (1997) Hindlimb deformities (ectromelia, ectrodactyly) in free-living anurans from agricultural habitats. *Journal of Wildlife Diseases* 33(1): 95–104. <https://doi.org/10.7589/0090-3558-33.1.95>
- Piha J, Pekkonen M, Merila J, Beaupre SJ (2006) Morphological Abnormalities in Amphibians in Agricultural Habitats: A Case Study of the Common Frog *Rana temporaria*. *Copeia* 4(4): 810–817. [https://doi.org/10.1643/0045-8511\(2006\)6\[810:MAIAIA\]2.0.CO;2](https://doi.org/10.1643/0045-8511(2006)6[810:MAIAIA]2.0.CO;2)
- Rojas-Morales JA, Escobar-Lasso S (2013) Notes on the natural history of three glass frogs species (Anura: Centrolenidae) from the Andean Central Cordillera of Colombia. *Boletín Científico Museo de Historia Natural* 7(2): 127–140. <http://ref.scielo.org/ydk5y3>
- Roy D (2002) Amphibians as environmental sentinels. *Journal of Bio-Science* 27: 187–188. <https://doi.org/10.1007/BF02704906>
- Sessions SK, Ruth SB (1990) Explanation for naturally occurring supernumerary limbs in amphibians. *The Journal of Experimental Zoology* 254(1): 38–47. <https://doi.org/10.1002/jez.1402540107>